Novel Four Layer Dressing Enhances Leg Ulcer Healing: Longitudinal Yarn Compression in Direct Contact with Wound Surface Delivers Effective Elastic Compression

Ischemic R Foot Ulcers x 18 Months

Problems

- Pain
- L BKA
- Paraplegia with knee contracture
- Tobacco use

Right ankle ulcer present for 18 months before acoustic powered debridement and HOCl irrigation. Note corrosive furrows are present to control wound surface edema.

Post Op dressing day #14. Layers over Apligraf: Polyester mesh, EdemaWear®, cast padding gauze wrap, Cobam

Observe exudate from 14 days after surgery.

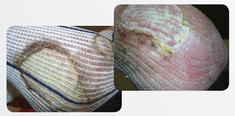

Note Longitudinal Yarn Compression (LYC) stockinet textile in direct contact with the healing wound surface as layer #1 of a four layer dressing.

Rx

- Aggressive bioburden control with acoustic debridement and hypochlorous acid irrigation
- Topical HEMA powder
- BioEngineered human skin substitute
- LYC four layer dressings



Day 14 dressing change after Apligraf placement. Note lateral ankle ulcer looks "rough". 14 days post BioEngineered skin substitute. Note corrosive furrows and white hydroxyethyl methacrylate (HEMA) Altrazeal on the healing surface.

Hydroxyethyl Methacrylate powder, Altrazeal is applied to the ulcer after LYC stockinet in place. Textile is lifted up and powder is "snow flaked" onto the healing surface

Wound debrided with 22.5 KHz hand piece was painful but tolerable for patient.

Outcome

- Ulcers heal 13 weeks after BioEngineered skin substitute and LYC compression

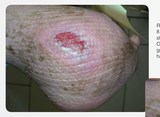

R ankle shows dramatic healing 8 weeks after BioEngineered skin substitute (Apligraf). Observe corrosive furrows in the wound-healing surface. Pain has dramatically decreased.

Dramatic, "miraculous", healing of the right ankle in spite of profound ischemia. In addition to meticulous control of bioburden, Apligraf and EdemaWear®, the patient attributes healing to this "Lord's Prayer" Crucifix.

L Ankle Ulcers x 11 Months

Problems

Wound comorbidities:

- AODM
- Pain
- Refractory to weekly wound clinic treatment

Left lateral ankle ulcer not responding to honey. Comorbidities include AODM, mild PVP, obesity, pain and venous insufficiency.

SonicOne® hand piece comfortable and completely debrides these diabetic ulcers.

Note corrosive in skin. Pain precluded adequate debridement with curette. As a result robust bioburden persists and precludes healing. Wound healing progressed quickly after 22.5 KHz acoustic powered wound debridement with HOCl irrigation (Vashe® PuriCore, Inc).

Medium size EdemaWear®, yellow stripe, is used as first layer of a four layer dressing.

Rx

- Bioburden control with acoustic debridement and hypochlorous acid irrigation
- Topical HEMA powder dressing
- LYC four layer dressings
- BioEngineered human skin substitute

Outcome

- Ulcers heal 9 weeks after Bio Engineered skin substitute and LYC Four Layer Dressing

Healing is complete 9 weeks after Apligraf. These wound were refractory to 9 months of weekly treatment with honey in a wound center. Note corrosive furrows in skin.

L Calf Venous Leg Ulcers

Problems

Wound comorbidities:

- Pain
- Poorly controlled AODM

Recurrent stasis ulcer with wound comorbidities: poorly controlled AODM, language barrier, limited resources and pain. Because of pain, this wound was not adequately debrided after 5 debridement sessions over 8 weeks. SonicOne® debridement with hypochlorous acid irrigation/HOCl effectively "cleans up" the bioburden in these lesions. Note that most of the bioburden is thick layers of dried serum that seeped from the inflamed ulcers.

Severe stasis dermatitis with weeping serum and heavy bioburden.

SonicOne 22.5KHz device arrives at Omaha Bergan Wound Clinic for a trial. 22.5KHz hand piece renders complete debridement in two settings.

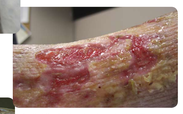

Two SonicOne debridement sessions make a huge difference in the healing progress of these stasis ulcers.

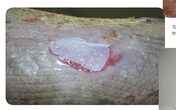

Apligraf covers the lateral calf ulcer. BioEngineered skin substitute (Apligraf) on medial ulcer.

Four layer dressing, with EdemaWear® as layer #1, stabilized the Apligraf. Components of the EdemaWear® Four Layer Dressing.

Rx

- Aggressive bioburden control with acoustic debridement and hypochlorous acid irrigation
- Topical HEMA powder dressing
- BioEngineered human skin substitute
- LYC four layer dressings

Outcome

- Ulcers heal 11 weeks after Bio Engineered skin substitute and LYC Four Layer Dressing

Wounds are 97% healed seven weeks after BeSS. Note skin corrosive furrows in the granulating wounds.

Observe the resolution of the severe stasis dermatitis.

Venous R Leg Ulcers

Problems

Wound comorbidities:

- Pain
- COPD on prednisone
- Arterial occlusive disease
- Pain precluded adequate debridement for several months

Painful stasis ulcers present for 14 months. Patient refused mechanical debridement. This eschar did not respond to Santyl. Note the severe stasis dermatitis in surrounding skin.

After several weekly wound clinic visits this wound is still not completely debrided because wound is exquisitely tender.

BioEngineered human skin substitute (Apligraf). Observe the improvement in stasis dermatitis in surrounding skin, the result of Longitudinal Yarn Compression textile (EdemaWear®).

Rx

- Bioburden control with acoustic debridement and hypochlorous acid irrigation
- Topical HEMA powder dressing
- BioEngineered human skin substitute
- LYC four layer dressing

Hydroxyethyl Methacrylate powder (Altrazeal) dressing stabilizes the BioEngineered skin substitute (Apligraf).

Small EdemaWear® being stretched over the Longitudinal Yarn Compression textile (LYC) covered by polyester mesh. EdemaWear® is the first layer of a four layer dressing. EdemaWear® provides the elastic engine of the four layer "post op dressing".

Cast padding is layer #2 of four layer loosely wrapped Post Op dressing to stabilize the BioEngineered skin substitute.

Outcome

- Ulcers heal 13 weeks after BioEngineered skin substitute and LYC Four Layer Dressing

EdemaWear® has "treated" the severe stasis dermatitis and wounds have healed.

Authors:

Martin J. Winkler, MD, FACS
University of Nebraska College of Medicine, Omaha, Nebraska
Creighton University College of Medicine, Omaha, Nebraska

Laura A. Wisnieski, RN, CWN
Alegent Health Bergan Mercy Wound Clinic, Omaha, Nebraska

Roy Norris
Creighton University College of Business, Omaha, Nebraska

Novel Four Layer Dressing Enhances Leg Ulcer Healing: Longitudinal Yarn Compression in direct contact with wound surface delivers effective elastic compression.

Introduction: Control of wound exudates, lymphorrhea and minimal wound pain from elastic compression are major advantages of layered dressings. Four layer compression dressings are standard therapy for leg ulcers resulting from lymphedema and venous insufficiency. (1, 2)

Kozeny reported a novel textile stockinet, Longitudinal Yarn Compression® (LYC) for edema in 2006.(3) LYC stockinet delivers compression via fuzzy yarn to one fifth of the skin surface, leaving four fifths of the subcutaneous fat uncompressed. Conceptually, patent lymphangions (micro-anatomic term for a lymph vessel unit with smooth muscle and tissue valves) in noncompressed subdermal fat provide effective lymph fluid drainage from zones of elastic compression.

Fuzzy yarn contact with the skin has advantages that are poorly understood. Fuzzy skin nexus may down regulate skin nociceptive reflex arcs to decrease pain and increase skin oxygen content by reflex control of cutaneous microcirculation.

Patent lymphangions and "fuzzy skin nexus" are physiologic advantages. This first human use study asks two questions: Is LYC textile comfortable and safe as the compression generating first layer of a four layer dressing? Is LYC textile superior to ACE type elastic wraps as the elastic compression generating engine of a four layer dressing?

Methods: Four patients were treated with four layer dressings. Layer #1: LYC elastic textile, #2: A "therapeutic" layer of foam, alginate powders, etc. above layer #1 but in contact with the granulation tissue, #3: Cast padding, #4: Cobam. Photos document treatment and healing.

Results: Patients reported the dressing was "comfortable" (pain free) within 2 hours of application. All wounds healed.

Conclusions: (1) Delivering elastic compression with fuzzy yarns ("fuzzy skin nexus") down regulates nociceptive reflex arcs in the skin and appears to decrease wound pain due to compression dressings.

(2) Fuzzy longitudinal yarn elastic textile, as the compression engine of a multilayered dressing appears more effective for wound healing than ACE type elastic wraps..

References:

(1) Nicky Cullum, Trevor A Sheldon. A systematic review of compression treatment for venous leg ulcers. BMJ 1997;315:576-580.

(2) E. A. Nelson, C. P Iglesias, N. Cullum, D. J. Torgerson. Randomized clinical trial of four-layer and short-stretch compression bandages for venous leg ulcer. BMJ 1997;315:576-580.

(3) Longitudinal yarn compression textile: An innovative treatment for leg swelling, Journal of Vascular Nursing, Volume 25, Issue 3, Pages 62-62, D. Kozeny, K. Stott, 2006.

***EdemaWear®, Compression Dynamics LLC, Omaha, Nebraska**

National Science Foundation Grant Award Number 0650233

University of Nebraska Medical Center

Creighton University School of Medicine

www.CompressionDynamics.com