Methyl Folate Palliates Pain in Chronic Stasis Ulcers Under Treatment with Elastic Compression

Ischemic Limb Pain With Paraplegic Neuropathic Pain

Problem:

- Right foot pain poorly controlled with OxyContin and Depakote

Painful right foot ulcers in a patient with L BKA who refuses amputation. Co morbidities include paraplegia, arterial occlusive disease, neuropathy, possible Burger's disease and narcotic dependence for back injury-neuropathy-paraplegia.

Right foot redness and swelling belie the stage set for pain due to inflammation, ischemia, traumatic neuropathy and an open wound.

Right ankle ulcer nearly healed after bioengineered skin substitute and a painful 8 month struggle.

Right 5th metatarsal head ulcer healed.

Outcome:

- Oral Methyl Folate * brings relief to pain

Neglected Recurrent Stasis Ulcers

Patient returned to wound clinic with recurrent stasis ulcers after three months of inadequate elastic compression, no leg elevation and no local care of the skin. Seen here is the 22.4 kHz ultrasound hand piece***. Ultrasound debridement controlled granulation bioburden in the stalled recurrent stasis wound§.

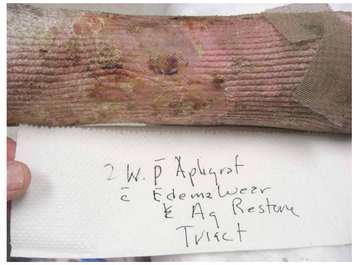

Healing of wound nearly complete after 9 weeks of wound clinic treatment with: ultrasonic *** debridement for control of bioburden, Longitudinal Yarn Compression**** and bioengineered human skin substitute**.

Problems:

- Wound pain disturbed sleep leading to depression.
- Wound Co morbidities:
- Limited resources for travel, hygiene, self care and medications
- Poor nutrition
- Tobacco use

Extensive scarring and fibrosis of skin surface gives this chronic stasis ulcer the appearance of a burn.

Outcome:

- Painful wounds interfered with sleep and caused depression.
- Pain was poorly controlled on OTC medication. Oral methyl folate* provided patient with significant pain palliation starting at treatment week # 4.
- He returned to the clinic smiling.
- Wounds healed after 9 weeks of treatment with Longitudinal Yarn Compression and bioengineered human skin substitute.

Recurrent Stasis Ulcers

Chronic leg ulcers due to venous insufficiency with severe stasis dermatitis in the surrounding skin. Note redness and edema in the surrounding inflamed skin.

Healed stasis ulcers after 7 months of Longitudinal Yarn Compression Textile**** and two applications of Bioengineered human Skin Substitute**. Note the cornrow furrows in the skin.

Problems:

- Patient has refused sharp debridement for 4 months because of tenderness and pain
- Co morbidities:
  - Octogenarian, veteran of the Japanese Occupation
  - Atherosclerotic occlusive vascular disease COPD – on Prednisone and home oxygen

Chronic leg ulcers with severe stasis dermatitis. Note edema and redness of the surrounding skin.

Outcome:

- Tenderness and pain responded to poorly oral narcotics and OTC pain pills. Oral Methyl Folate* palliated pain starting at treatment week 20.
- Stasis dermatitis is accompanied by ischemic "neuritis" associated with low skin oxygen levels. Methyl folate increases capillary nitrous oxide in the perineuronal micro circulation. Nitrous oxide is a capillary smooth muscle vasodilator that increases capillary flow and 0_2 delivery to inflamed neurons.

Steven L. Clinch, MD, FACS
Martin J. Winkler, MD, FACS
Karla A. Manzel, BSN, MS, CWON, FCN
Lindsey Manzel BS

Introduction:
Oral methylfolate (*) is indicated for the treatment of diabetic neuropathy and commonly palliates the pain accompanying diabetic neuropathy (1) The mechanism of methylfolate is increased capillary blood flow to the long neurons. Folate, elevates endothelium nitric oxide(NO) a gaseous free radical. NO dilates the capillary smooth muscle and blood flow increases. Nitric oxide is a critical mediator of normal tissue repair.(2) L-methylfolate increase endothelial tetrahydro-L-biopterin, an enzyme cofactor that increases NO production from arginine. We observed that patients taking methylfolate seemed to have less pain from elastic compression of chronic stasis ulcers. This study asks, "Does oral methylfolate palliate wound pain?"

Methods:
Five patients treated in a community wound care clinic for chronic painful wounds were given oral methylfolate for four weeks. Most patients were treated continuously with yarn focused elastic compression for control of limb edema(****). No changes were made in the pain treatment regime. Patients were treated with multiple combinations of oral narcotics, OTC pain medications (e.g. aspirin or acetaminophen), antidepressants (e.g. bupropion) and low dose tricyclic antidepressants prescribed specifically for chronic pain. After four weeks, patients were allowed to choose to continue methylfolate replacement or not, based on the individual's perception of efficacy.

Findings:
Patient assessment of wound pain documented at each wound center visit with a protocol. Wound healing in each subject is documented with color photographs.

Conclusions:
Oral methylfolate, in a non controlled, anecdotal, clinical series, appears to palliate pain in chronic leg ulcers treated with elastic compression.

References:
1 VanEtten, R.W., et al, Impaired NO-dependent vasodilation in patients with Type II (non-insulin-dependent) diabetes mellitus is restored by acute administration of folate. Diabetologia 2002; 45:1004-1010.

2 Schwentker, A., Nitric oxide and wound repair. Surg Clin North Am. 2003; 83(3):521-530.

Product Legend:

* Metanx®, Pamlab LLC, Covington, LA

**Apligraf ®, Organogenesis Inc., Canton, MA

*** SonicOne®, Misonix, Farmingdale, NY

**** EdemaWear®, Compression Dynamics LLC, Omaha, NE

Institutional Sponsor :
Bergan Mercy Hospital
Wound Care Clinic, Omaha, Nebraska

www.CompressionDynamics.com